Proceedings of the 7th International Conference on Mechanics and Materials in Design,
Albufeira/Portugal 11-15 June 2017. Editors J.F. Silva Gomes and S.A. Meguid.
Publ. INEGI/FEUP (2017)

PAPER REF: 6972

A DECISION SYSTEM FOR PLAQUE DETECTION IN THE CAROTID ARTERY

Catarina F. Castro(*), Luisa C. Sousa, Carlos C. António
FEUP/INEGI, University of Porto, Porto, Portugal
(*)*Email:* ccastro@fe.up.pt

ABSTRACT

Carotid Doppler ultrasound and imaging are focused on the visualization and measurement of blood flow providing critical diagnostic information noninvasively about fluid dynamics and abnormalities. Ultrasound imaging is a complicated interplay between physical principles and signal processing methods. In this work a two-step methodology to predict carotid plaque disruption is reported. An automatic technique based on row wise pixel intensity distribution alleviates the laborious and time consuming manual evaluation and classification of the carotid artery intima-media thickness. Selected image-based parameters, extracted from pixel intensity information and associated with risk score of carotid atherosclerotic plaques, were introduced in an artificial neural network model the feasibility of possible development of neurological complications due to plaque disruption.

Keywords: algorithms, ultrasound image segmentation, carotid plaque status.

INTRODUCTION

The process of carotid arterial narrowing represents a long-term chronic disease. In the initial phase, fatty deposits affect the inner lining of the vessel developing a plaque. Symptoms and adverse effects are noted when vulnerable or high risk plaques ulcerate associated to a high risk of causing stroke. Other vulnerable plaques progress rapidly. The factors that determine the risk of a carotid plaque resulting in a stroke include luminal stenosis, plaque composition, and plaque morphology. Carotid sonography offers insight into the nature of carotid plaques based on the amount of lipid material in the plaque and the presence of ulcerations. Carotid sonography, a fast and inexpensive technique, is extremely useful in the initial evaluation of symptomatic patients who present nonspecific symptoms related to stenotic or embolic accidents. Current ultrasound scanners generate accurate cardiovascular measures safely, rapidly and relatively inexpensively. Ongoing projects are planned to generate vascular images for hundreds of thousands of individuals in different countries that, over the next few years, can be used to determine the true value of vascular imaging for disease prediction (World Heart Federation, 2015).

Ultrasound enables the acquisition of longitudinal and cross-sectional images of the carotid artery bifurcation and image segmentation provides data to construct carotid luminal surface. With increased automation and functionality, it may be possible in future to routinely examine people with ultrasound to establish cardiovascular disease present before symptoms emerge, so that future disease can be prevented, for example using medication. Symptomatic carotid artery disease is associated with plaque neovascularization, intra plaque haemorrhage, and invasion of inflammatory cells. Hypo echogenicity is already well established as a marker of high-risk carotid lesions (Partovi et al. 2012). Tissue Doppler imaging allows evaluating

plaque characteristics such as tissue elasticity and the velocity at which tissue deformation occurs. More experience and data are necessary to facilitate the visualization of the transitional zone between an intra plaque thrombus and the less elastic fibrous tissue surrounding it (Kunte et al. 2013).

The segmentation of the common carotid artery (CCA) based on active contours are not the best choice for an automatic and accurate segmentation of the carotid artery wall, particularly, because the propagation forces of these models are based on image intensity gradient information, often stuck in regions associated to local minimal solutions (Cheng et al. 2011; Ma et al. 2010). Also, parametric snakes normally require manual initialization, with the definition of an initial contour closest to the carotid boundaries, and constant human intervention to improve the segmentation results (Loizou et al. 2014; Ma et al. 2010). Based on region growing methodology, a new technique is applied to segmentation of B-mode ultrasound images ensuring convergence from lumen identification to lumen boundary. This method consists of a two-step method including the identification of an ultrasound profile of the active plaque and the computation of a risk score.

MATERIALS AND METHODS

Carotid artery disease diagnosis greatly depends upon accurate artery image segmentation. To obtain better segmented image, noise must be removed. For this purpose, we have used median filter for noise removal as image pre-processing step. It is a non-linear filter and preserves the image detail in better way. The main objective of object separation from background is to separate out the objects from image background considering it as a two class problem (background and the objects). The algorithm calculates the optimal threshold to separate the objects from background so that the intra-class variance becomes minimal. Some isolated and noisy patterns may remain there. These noisy patterns are removed through morphological opening operation usually used for smoothing the object contours and for elimination of thin protrusions. After the opening morphological operation, the area inside the artery walls needs to be identified. The most common error for false-positive diagnosis of occlusion is superimposition of the external and internal carotid in the coronal plane, the internal carotid is mistakenly considered to be obstructed. The possibility exists that external carotid branches have been imaged and the internal carotid is occluded. Suspicion that external carotid branches have been imaged is further heightened if a clear difference exists in the pulsatile quality of signals heard at one bifurcation but not at the other. Fig. 1 the region of interest selected from an original carotid artery ultrasound image. To reduce the speckle noise and wave interferences, median filter were applied on the original image.

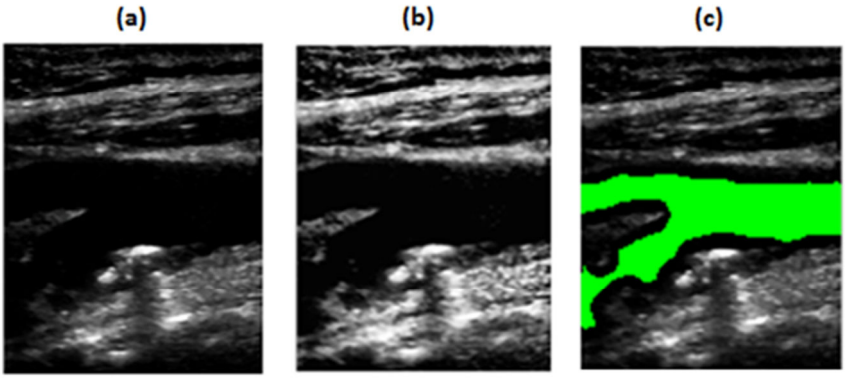

Fig. 1 - Lumen segmentation main steps: (a) Selection of the region of interest; (b) Increased overall image contrast; (c) Identification of lumen central region.

Intima-media thickness measurement is one of the effective techniques for the detection of the plaque into the carotid artery. Five features, namely, the average, variance, standard deviation, skewness and kurtosis are extracted from measured values used to train and test the classifier.

Automatic morphological parameter identification such as degree of stenosis, evidence of plaque disruption, presence of echogenic cap, plaque echo-structure appearance and location of the echo lucent region in heterogeneous lesions are the main purpose of image analysis motivated for the need of developing new strategies for plaque status characterization.

Traditional strategies of plaque risk prediction include the Activity Index (AI) and the degree of stenosis (DS). Following previously presented methodologies providing effective selection of plaques at high risk of developing symptoms (Seabra et al. 2011) the Enhanced Activity Index (EAI) technique quantifies the likelihood of a stable plaque to becoming symptomatic. This method consists of a two-step method including the identification of an ultrasound profile of the active plaque and the computation of a risk score: plaques showing EAI > 1 are prone to produce symptoms, being more dangerous as EAI increases. The main purpose of the present work is the automatic identification of an ultrasound profile of the active plaque.

Seabra et al. (2011) presented the significant parameters and corresponding sources of the optimal feature set for plaque description, namely, 16-element feature set both subjective (given by experienced physicians) and objective image-based parameters (extracted from pixel intensity information) were selected. Image-based parameters being: degree of stenosis, histogram features, echo-morphology descriptors and textural features. The purpose of the work presented here is to perform a combination of the last three parameters in order to infer stroke risk discriminating between plaques with stable lesions and plaques with lesions prone to developing neurological complications.

Artificial neural networks (ANNs) are computer programs designed to simulate the way brain processes information. ANNs are trained based on examples and can be valuable to construct a decision maker based on knowledge only.

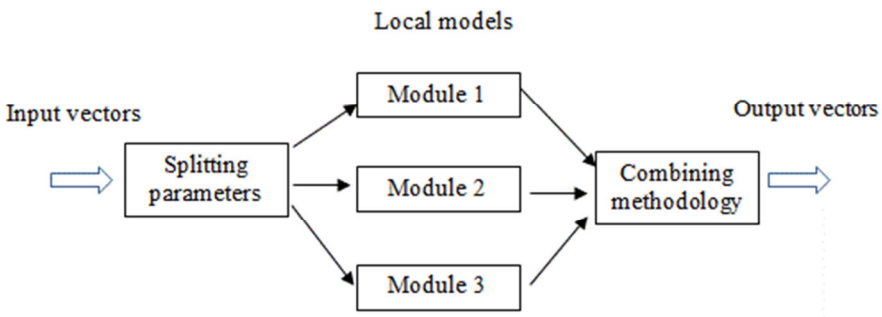

Fig. 2 - Modular approach based on local specialized models.

There is no theoretically sound way of choosing the optimal ANN architecture for each separate model. The considered network has one hidden layer with N neurons. Synapses send data on to a hidden layer, which in turn sends to the output layer representing the dependent variables. Input and hidden layer biases need to be adjusted in all learning algorithms of neural networks and thus there exists dependency between different layers of parameters (weights and biases). The activation functions (hyperbolic tangent functions), the weights of the synapses and the bias applied to the neurons at the hidden and output layers are to be controlled during the supervised learning process. In this particular classification problem, generalization is a central issue, because severe clinical consequences can result from the decrease of performance. The activation function of the last layer of the network is a linear transfer function.

CONCLUSION AND FUTURE WORK

The proposed approach successfully segment and classify carotid artery images in an automated way identifying plaque lesions at high risk of becoming symptomatic. ANN modelling quantifies the likelihood of a stable plaque to becoming symptomatic. It has been previously accepted that the benefit of surgical intervention based on the degree of stenosis alone as a decision making criterion is low in the asymptomatic disease and in symptomatic disease with moderate obstruction motivates the need for developing new strategies plaque status characterization. Although user dependant, the implemented methodology allows the user to load images and process and extract features enabling plaque detection and discrimination. Limitations similar to other technologies are expected to be resolved with further studies and technical improvements. The present research contributes to the analysis of hemodynamic conditions of the carotid bifurcation stenosis and occlusion.

ACKNOWLEDGMENTS

The authors gratefully acknowledge the funding by FCT, Portugal, of the Research Unit of LAETA-INEGI, Faculdade de Engenharia da Universidade do Porto.

REFERENCES

[1]-Cheng, D.C., Billich, C., Liu, S.H., Qiu, Y.C., Shen, Y.L., Brambs, H.J., Trucksass, A.S., Schutz, U.H.W.: Automatic detection of the carotid artery boundary on cross-sectional MR image sequences using circle model guided dynamic programming. BioMedical Engineering OnLine 10:26 (2011) doi:10.1186/1475-925X-10-26.

[2]-Kunte L, Ruckert RI, Schmidt C, et al. (2013) Detection of unstable carotid plaque by tissue Doppler imaging and contrast-enhanced ultrasound in a patient with recurrent amaurosis fugax. Case Rep Vasc Med 2013:354382. doi:10.1155/2013/354382

[3]-Loizou, C.P., Theofanous, C., Pantziaris, M., Kasparis, T.: Despeckle filtering software toolbox for ultrasound imaging of the common carotid artery. Computer Methods and Programs in Biomedicine, 114(1), 109-24 (2014)

[4]-Ma, Z., Jorge, R.N., Mascarenhas, T., Tavares, J.M.R.S.: A Review of Algorithms for Medical Image Segmentation and their Applications to the Female Pelvic Cavity. Computer Methods in Biomechanics and Biomedical Engineering. 13, 235-246 (2010).

[5]-Partovi S., Loebe M., Aschwanden M. et al., Contrast-enhanced ultrasound for assessing carotid atherosclerotic plaque lesions, American Journal of Roentgenology, vol. 198, pp. W13-W19, 2012.

[6]-Seabra J., Pedro L., Fernandes J., Sanches J. Ultrasound plaque enhanced activity index for predicting neurological symptoms, in Pattern Recognition and Image Analysis (Lecture Notes in Computer Science.Berlin, Germany: Springer-Verlag,, 184-191 (2011).

[7]-World Heart Federation. (2015, January 12). Can ultrasound detect potential heart attacks, stroke before symptoms arise. ScienceDaily. Retrieved April 5, 2017 from www.sciencedaily.com/releases/2015/01/150112191338.htm.