An annotation tool for dermoscopic image segmentation

P. M. Ferreira
Faculdade de Engenharia,
Universidade do Porto
Porto, Portugal
meb09015@fe.up.pt

T. Mendonça
Faculdade de Ciências,
Universidade do Porto
Porto, Portugal
tmendo@fc.up.pt

P. Rocha
Faculdade de Engenharia,
Universidade do Porto
Porto, Portugal
mprocha@fe.up.pt

J. Rozeira
Hospital Pedro Hispano
Matosinhos, Portugal
jrozeira@me.com

ABSTRACT

Dermoscopy is a non-invasive diagnostic technique for the *in vivo* observation of pigmented skin lesions, and it is currently one of the most important imaging techniques for melanoma diagnosis.

Since the diagnostic accuracy of dermoscopy significantly depends on the experience of the dermatologists, and the visual interpretation and examination of this kind of images is time consuming, several computer-aided diagnosis systems of digital dermoscopic images have been introduced.

However, a reliable ground truth database of manually segmented images is necessary for the development and validation of automatic segmentation and classification methods. As the ground truth database have to be created by expert dermatologists, there is a need for the development of annotation tools that can support the manual segmentation of dermoscopic images, and this way make this task easier and practicable for dermatologists.

In this paper we present an annotation tool for manual segmentation of dermoscopic images. This tool allows building up a ground truth database with the manual segmentations both of pigmented skin lesions and of other regions of interest, whose recognition is essential for the development of computer-aided diagnosis systems.

Categories and Subject Descriptors

D.2.2 [**Software Engineering**]: Design Tools and Techniques—*User interfaces*; H.2.8 [**Database Management**]: Database Applications—*Image databases*; I.4.0 [**Image Processing and Computer Vision**]: General—*Interactive environments*; I.5.5 [**Implementation**]: Interactive systems; J.1 [**Administrative Data Processing**]: Education; J.3 [**Life and Medical Sciences**]: Medical inform systems

General Terms

Algorithms, Standardization

Keywords

Dermoscopy, image segmentation, ground truth dataset

1. INTRODUCTION

Skin cancer is one of the most common cancers in humans. Malignant melanoma is the most deadly form of skin cancer, and its incidence has been rapidly increasing over the last years. Successful treatment of melanoma depends directly on early diagnosis, because when detected in an early and non-invasive stage, the malignant melanoma can surgically be removed (excised) with an excellent prognosis for the patient [2, 3].

In order to improve the accuracy of melanoma diagnosis various imaging techniques have been explored. Among these, dermoscopy is clinically one of the most relevant imaging techniques for pigmented skin lesions diagnosis. Dermoscopy is a non-invasive diagnostic technique for *in vivo* observation, allowing a better visualization of the surface and subsurface structures, and the recognition of morphologic structures not visible by the naked eye [1, 4].

The increasing demand for dermoscopic exams calls for the development of computer-aided diagnosis systems that can assist the clinicians. In this context the development of a ground truth database is of crucial importance [6].

In this paper we propose an annotation tool for setting up a ground truth database of manually segmented dermoscopic images. This is a customized tool for dermoscopy, but can easily be adapted to other medical imaging applications. The presented tool allows segmenting a pigmented skin lesion from the image, and also performing the segmentation of other regions of interest, such as regions with different colors, typical or atypical vascular networks, dots, globules, star burst patterns, etc.

To accomplish this purpose, this tool has several functionalities including: image upload and display, manual segmentation, region labeling, boundary reshaping, *a posteriori* boundary edition, multi-user ground truth annotation and segmentation comparison, and storage of the segmented im-

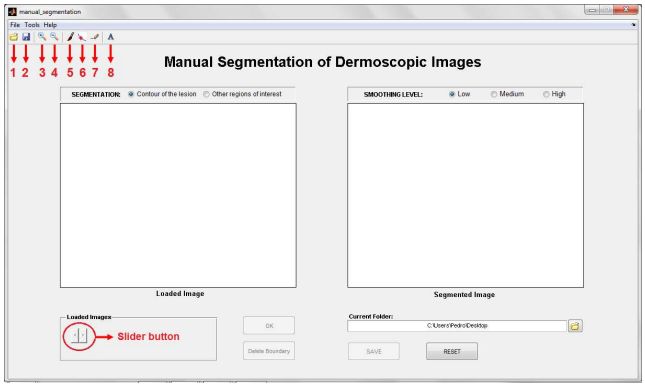

Figure 1: Initial aspect of the graphical interface. Toolbar Buttons: 1-"Load Images"; 2-"Save as"; 3-"Zoom in"; 4-"Zoom out"; 5-"Manual segmentation"; 6-"Pointwise boundary reshaping"; 7-"Local boundary reshaping"; 8-"Region labeling".

ages. Taking its functionalities into account this tool has some advantages with respect to other existing annotation tools, namely better freehand drawing and boundary reshaping functionalities.

2. ANNOTATION TOOL DESCRIPTION

This application allows performing the manual segmentation of dermoscopic images and storing the result of segmentation. For this purpose, the user has a set of tools to be used sequentially to achieve the desired result. The main functionalities of this interface are:

(i) Image upload and display;

(ii) Manual segmentation (of the lesion or other regions of interest);

(iii) Region labeling;

(iv) Boundary reshaping;

(v) *A posteriori* boundary edition;

(vi) Multi-user ground truth annotation and segmentation comparison;

(vii) Storage of segmented image.

The graphical interface was set up based on the requirements and suggestions of dermatologists and was implemented in a MATLAB environment (7.9.0 R2009b) taking into account its image processing toolbox and graphical facilities. Figure 1 shows the initial aspect of this graphical interface.

2.1 Image upload and display

With this application it is possible to open one image or several images at once. For this purpose, it is necessary to select the option "Load images" in the "File" menu, or simply press the button 1 on the toolbar, Figure 1.

Then a dialog box appears that enables the user to browse and select the image to be segmented. To open multiple images, simply press CTRL key and select the desired images.

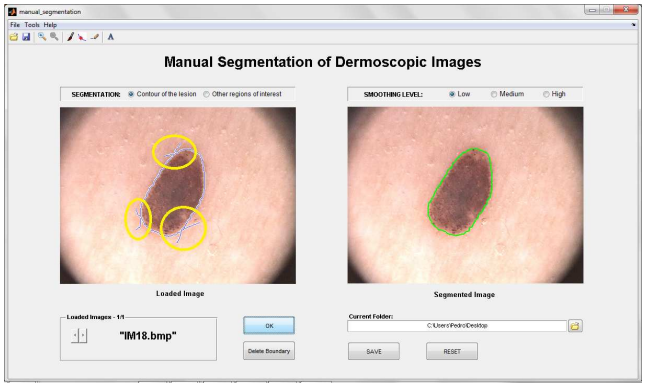

Figure 2: Image on the left: initial contour drawn by the user, with some undesirable extra lines (marked with circles). Image on the right: final contour after morphological filtering. Note that the final contour is smoother than the initial and without undesirable extra lines.

The loaded image is displayed on the left side of the interface. If several images have been loaded, the user can easily change the image that is being displayed through the slider button, Figure 1.

2.2 Manual segmentation

In order to perform the manual segmentation, this application allows to draw a freehand region of interest on the loaded image. It is important to note that the manual segmentation can be performed using a pen tablet or a mouse. The user can choose between performing the manual segmentation of the lesion or other regions of interest through the radio buttons on the panel "segmentation".

To achieve the manual segmentation it is necessary to select in the "Tools" menu the option "Manual Segmentation", or simply press the button 5 on the toolbar, Figure 1. Then, the user must click and drag the pen tablet to draw the contour of the lesion (or the contour of other regions of interest).

When the user confirms the segmentation, the image with the final contour is displayed on the right side of the interface, Figure 2.

Note that the user can only confirm and complete the segmentation when a closed contour is drawn. When the user lifts the pen from the tablet before closing the contour, the contour remains open. However, while the contour is open there is the possibility of resuming drawing until the user completes and closes the contour.

To our knowledge other available manual segmentation tools, such as ImageJ, do not have this possibility, since when the drawing is interrupted the contour is automatically closed with a straight line between the beginning and the end point.

To obtain the final contour from the initial one (drawn by user), a binary mask of the initial contour is first created, in which pixels with intensity value of 1 correspond to the segmented object, while pixels with value 0 correspond to the background. Then a morphological filtering is applied

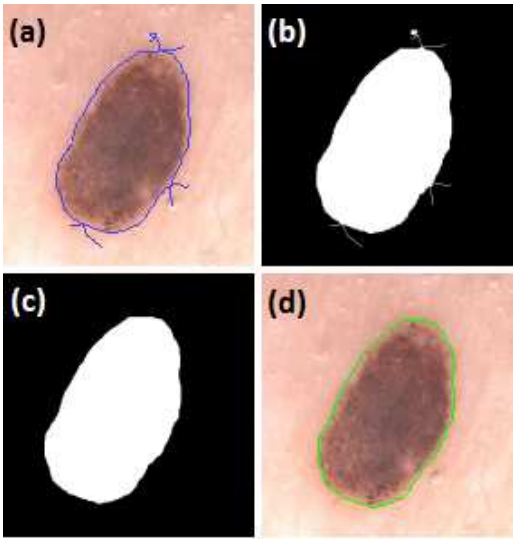

Figure 3: Morphological filtering: Initial contour drawn by the user (a), Binary mask of initial contour (b), Binary image after morphological filtering (c), and Final contour obtained from image "c" (d).

to this binary mask in order to smooth and remove extra lines that not belong to the contour. These lines may arise when the contour is drawn by means of multiple segments, especially at the points of intersection of these segments, Figures 2 and 3.

Basically, morphological filtering is divided into three stages (i) morphological erosion; (ii) selection of the biggest binary object from the image and (iii) morphological dilation. The user also has the possibility to select the degree of smoothing of the morphological filter between low, medium and high. In each of these morphological operations a flat disk-shaped structuring element is used, with a specific radius for each smoothing level (low: radius 1; medium: radius 3; high: radius 7).

The manual segmentation of other regions of interest can be done in a very similar procedure to the manual segmentation of the lesion. For this purpose, the user must select the "Other regions of interest" radio button in the panel "Segmentation", and perform the segmentation of the desired regions in the same way as for the whole lesion. The contours of all segmented regions are shown simultaneously in the right window, Figure 4.

2.3 Region labeling

Another available functionality of this graphical interface is "Region labeling", which was developed based on the suggestions of dermatologists and allows labeling the segmented regions. The user must select the option "Region labeling" in the "Tools" menu, or simply press the button 8 on the toolbar, Figure 1.

Afterwards, the user should move the pointer over the desired segmented region and click on it. This produces another window where a number of default labels are available for selection. These labels include the main dermoscopic

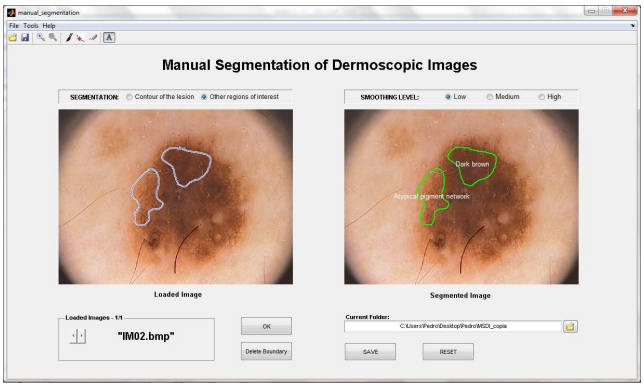

Figure 4: Segmentation example of other regions of interest with the respective labels.

features and also the six typical colors that can be present in a dermoscopic lesion, Figure 5. The possibility of making a different annotation is also available.

After selecting the desired label for each segmented region, the corresponding text annotation is placed inside the respective region, Figure 4.

2.4 Boundary reshaping

Even after finishing the manual segmentation it is possible to make some adjustments in the contour, if necessary. Two distinct methods were implemented to reshape the contour previously done, namely "Pointwise boundary reshaping" and "Local boundary reshaping".

To our knowledge other available manual annotation tools, for instance ImageJ, do not offer this possibility, and hence this is another advantage of our manual segmentation tool.

2.4.1 Pointwise boundary reshaping

This method must be used to make small adjustments in the contour, because the reshaping is done point-by-point. For this, the user must select the option "Pointwise Boundary Reshaping" in the "Tools" menu, or simply press the button 6 on the toolbar, Figure 1. Forthwith the boundary turns red with some control points. From these points it is possible to change the shape of the contour. For this, the user must click and drag the control points to their new positions, Figure 6. The interactive behaviors supported by this tool are described below:

1. **Boundary Reshaping:** Move the pointer over a control point. The pointer changes to a circle. Then, click and drag the control point to its new position.
2. **Adding a new control point:** Move the pointer over the boundary and press the **A** key. Click the left mouse button to create a new control point at that position on the boundary.
3. **Deleting a control point:** Move the pointer over a control point. The pointer changes to a circle. Then, click the right mouse button and select the option "Delete Vertex" from the context menu.

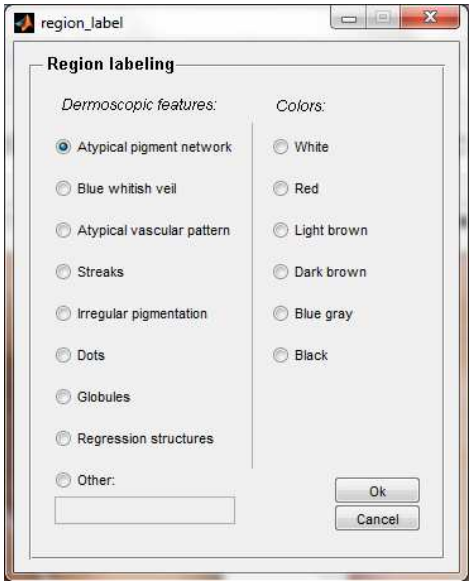

Figure 5: "Region labeling" window, in which there are several default labels that the user can select.

2.4.2 *Local boundary reshaping*

This method should be used when it is necessary to make great adjustments in the initial contour. For this, the user must select the option "Local Boundary Reshaping" in the "Tools" menu, or simply press the button 7 on the toolbar, Figure 1.

Basically, this method allows the user to draw a line to define the new shape of the contour. The line must intersect the initial contour at least in two points to form a closed contour. This can be used to increase or reduce the size of the initial contour. Note that it is possible to increase and reduce the size of the contour with a single line, Figure 7.

The final contour, Figure 7(h), is obtained through a set of logical, arithmetical, and morphological operations:

(i) First, a binary image from the initial contour and another binary image from the new line are created, Figure 7 (c) and Figure 7 (d) respectively;

(ii) Image subtraction between image (c) and (d), Figure 7 (e);

(iii) Selection of the biggest binary object from the image, and application of a logical OR operator between image (e) and (d), Figure 7 (f);

(iv) Application of a morphological filling in order to fill the image holes, and then a morphological open is used to remove the extra lines, Figure 7 (g).

2.5 A posteriori boundary edition

This functionality was implemented in order to allow the visualization and the edition of a previously existing segmentation. In this way, segmentation may be performed in a first stage by less experienced (or even non medical) staff and then corrected by specialists. This can be used

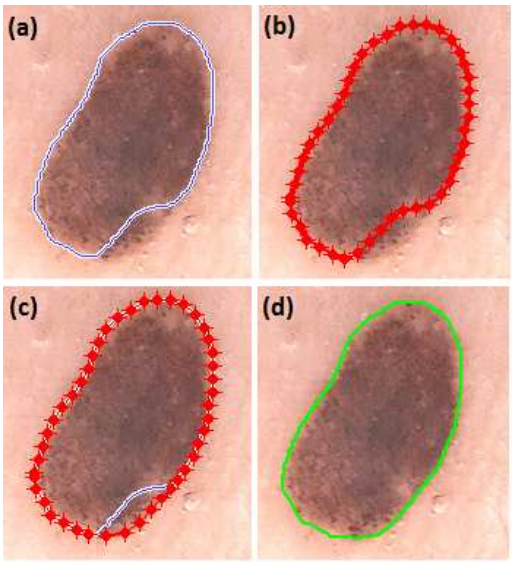

Figure 6: Pointwise boundary reshaping: Initial contour (a), Initial contour with control points to reshape the contour (b), Initial contour (solid line) and the reshaped contour (with control points) (c), and Final contour (d).

for medical training as well as for reducing the workload of the experts when building a ground truth database of large dimension.

Therefore, before starting the manual segmentation, the tool automatically searches in the current ground truth dataset if there exists a previously stored segmentation. In this case, the user can choose to visualize the previously existing contour and edit the border making use of the two existing boundary reshaping functionalities ("Pointwise boundary reshaping" and "Local boundary reshaping"). Otherwise, the user can discard the referred contour and execute a new manual segmentation following the proposed procedure.

2.6 Multi-user ground truth annotation and segmentation comparison

The manual segmentation of dermoscopic images is quite subjective and therefore it is desirable to collect segmentations performed by more than one dermatologist in order to create a reliable ground truth dataset [5]. In this regard, with this tool it is possible to segment and create annotations on the same image by different users. During the initialization of the interface the user can select an existing ground truth dataset (previously created by another user) or create his own new ground truth dataset (corresponding to his own segmentation), Figure 8.

As each user is associated to one ground truth dataset, this tool is capable of making the comparison between segmentations of different users for the same image. To accomplish this purpose visual and quantitative comparisons are both presented.

When this functionality is used for a given image another window is opened containing a list box with all datasets

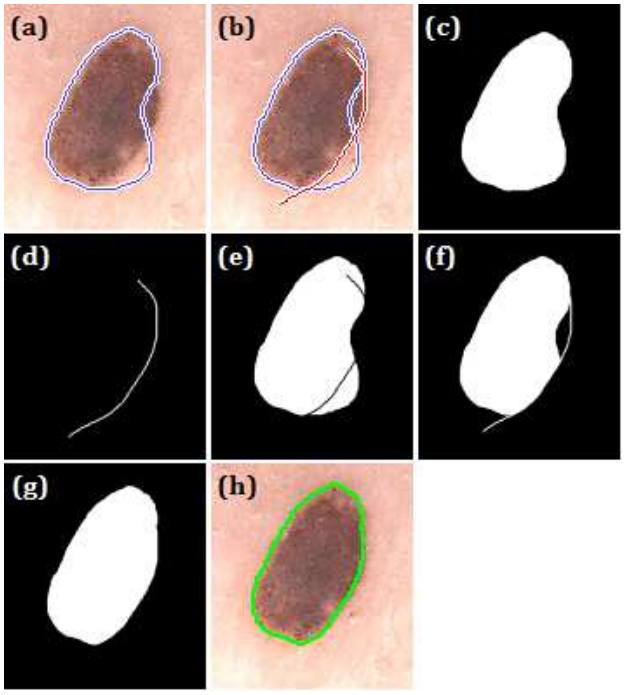

Figure 7: Local boundary reshaping: Initial contour (a), Initial contour and a new line to reshape the contour (b); Intermediate steps (c)-(g), and Final contour (h).

that have a segmentation of the current image for user selection. The user can compare his segmentation with the segmentations of one or more datasets, Figure 9.

For visual comparison the tool shows two or more segmentations on the same image. In addition, when only two segmentations are considered for comparison three performance metrics are given for the quantitative assessment of the segmentation discrepancies, namely the Hammoude distance, the false negative rate, and the false positive rate [6].

2.7 Storage of segmented image

Finally, this interface also allows storing the result of each manual segmentation. The ground truth dataset is created and organized automatically as the manual segmentations are stored. For each segmented image, a main folder with the same name of the image is created. In addition, two dedicated folders are created inside the main folder, one of them is for the storage of the manual segmentation of the lesion, and the other is for the storage of the manual segmentations of other regions of interest.

The segmentation result is saved as a binary image, where pixels with intensity value of 1 correspond to the segmented object, while pixels with value 0 correspond to the background. If different regions of interest were segmented, an individually binary image is created for each segmented region. Besides the binary image, a print of the original image with the contours of all segmented regions and the respective labels is stored. This image is created and stored since it provides a suitable global information of the manual segmentation.

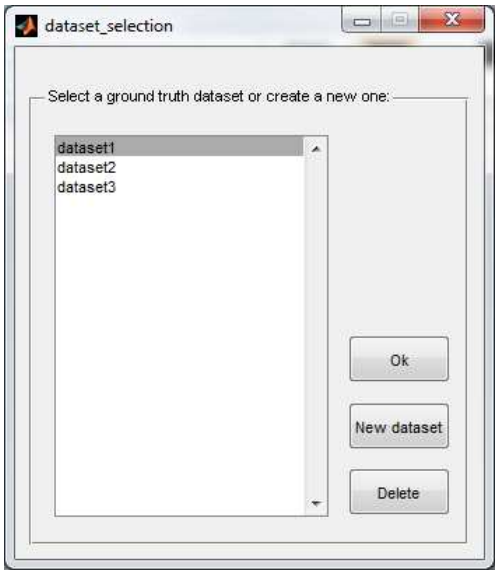

Figure 8: Window for ground truth dataset selection.

3. IMAGE ACQUISITION AND GROUND TRUTH CREATION

The clinical database of Hospital Pedro Hispano (HPH) has over 4000 cases with dermoscopic images of various types of lesions, all of them obtained under the same conditions through Tuebinger Mole Analyzer system. A total of 150 dermoscopic images were selected from the database along with the clinical diagnosis, being 70 melanocytic nevi (regular), 35 dysplasic nevi, and 45 melanomas. The images are in 24-bit RGB color, with 768x560 pixels.

In a first stage, the manual segmentation of 70 dermoscopic images (from the initial set of 150) was performed by hand in full sized printed images by Dr. Jorge Rozeira [1]. Afterwards, the set of manual segmentations were scanned and rectified. The contour of the lesions was identified on these digital images to produce a binary image for each lesion. Nevertheless, this procedure was cumbersome, and according to the expert dermatologist opinion the manual segmentation performed in a printed paper is not reliable enough in order to construct a ground truth dermoscopic image database.

Meanwhile, the remaining images are being segmented using the presented annotation tool and the proposed methodology. This procedure meets the wishes expressed by dermatologists who recognize a superior and adequate performance of the presented software tool for manual segmentation.

4. CONCLUSIONS

An annotation tool that can support the manual segmentation of dermoscopic images was presented in this paper. This tool allows building up, in a very simple and fast way,

[1] Co-author, and an expert dermatologist with over 10 years of experience in dermoscopic image analysis.

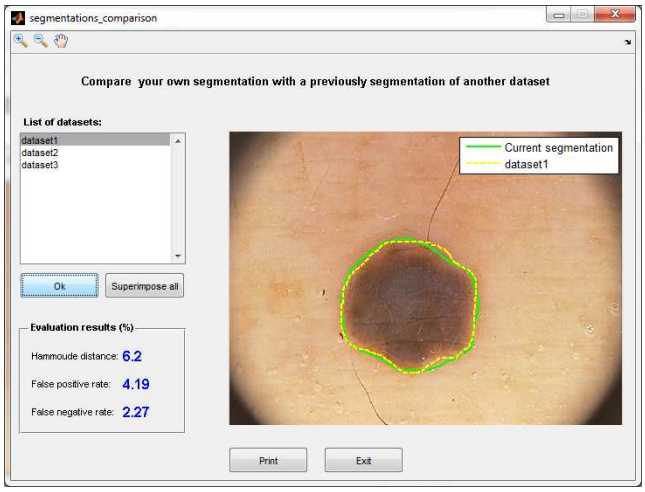

Figure 9: Segmentation comparison.

a ground truth database to be used in the assessment of automatic segmentation and classification methods.

This interface was developed based on the requirements and suggestions of dermatologists, and has been used by them in the creation of the ground truth database.

The main functionalities of this tool are: image upload and display, manual segmentation, region labeling, boundary reshaping, *a posteriori* boundary edition, multi-user ground truth annotation and segmentation comparison, and storage of the segmented images. Based on its functionalities, this tool offers some advantages with respect to other existing annotation tools, namely better freehand drawing and boundary reshaping functionalities.

Besides the manual segmentation itself, one of the most interesting tools is the boundary reshaping, with which the user can correct the shape of the contour previously done. To achieve this purpose , three distinct methods were implemented.

As future work some experimental results will be performed in order to validate this interface. This experimental results may include the analyze of the required times, user satisfaction, and also the comparison of our tool with others annotation tools beyond the ImageJ.

5. ACKNOWLEDGMENTS

The authors would like to thank Fundação para a Ciência e Tecnologia (FCT) for partially funding this research through the project ADDI (reference PTDC/SAU-BEB/103471/2008).

This work was also supported by FEDER funds through COMPETE-Operational Programme Factors of Competitiveness ("Programa Operacional Factores de Competitividade") and by Portuguese founds through the Center for Research and Development in Mathematics and Applications (University of Aveiro) and the FCT, within project PEst-C/MAT/UI4106/2011 with COMPETE number FCOMP-01-0124-FEDER-022690.

6. REFERENCES

[1] G. Argenziano, H. Soyer, V. D. Giorgio, D. Piccolo, P. Carli, M. Delfino, A. Ferrari, R. Hofmann-Wellenhof, D. Massi, G. Mazzocchetti, M. Scalvenzi, and I. H.Wolf. Dermoscopy, an interactive atlas. EDRA Medical Publishing, 2000. [ONLINE]. Available at: http://www.dermoscopy.org.

[2] A. Bono, C. Bartoli, N. Cascinelli, M. Lualdi, A. Maurichi, D. Moglia, G. Tragni, S. Tomatis, and R. Marchesini. Melanoma detection. a prospective study comparing diagnosis with the naked eye, dermatoscopy and telespectrophotometry. *Dermatology*, 205(4):362–366, 2002.

[3] G. C. Carmo and M. . R. Silva. Dermoscopy: basic concepts. *International Journal of Dermatology*, 47, 2008.

[4] T. M. Deserno. *Biomedical Image Processing*. Springer, 2011.

[5] X. Li, B. Aldridge, R. Fisher, and J. Rees. Estimating the ground truth from multiple individual segmentations incorporating prior pattern analysis with application to skin lesion segmentation. *Proceedings of 8th International Symposium on Biomedical Imaging (ISBI.11)*, pages 1438–1441, April 2011.

[6] M. Silveira, J. C. Nascimento, J. S. Marques, A. R. S. Marcal, T. Mendonca, S. Yamauchi, J. Maeda, and J. Rozeira. Comparison of segmentation methods for melanoma diagnosis in dermoscopy images. *IEEE Journal of Selected Topics in Signal Processing*, 3(1), February 2009.